

Prenatal diagnosis of partial lumbar asoma by two- and three-dimensional ultrasound and computed tomography: embryological aspects and perinatal management

C. HUISSOUD*†, C. BISCH*, K. CHARRIN*, R.-C. RUDIGOZ* and L. GUIBAUD‡

*Service de Gynécologie-Obstétrique, Hôpital de la Croix Rousse and ‡Département d'Imagerie Pédiatrique et Foetale, Hôpital Debrousse, Hospices Civils de Lyon, Université Claude-Bernard Lyon I, †INSERM U846, Stem Cell and Brain Research Institute, France Université de Lyon I, Lyon, France

KEYWORDS: computed tomography; prenatal; segmentation; spine; ultrasound; vertebra

ABSTRACT

Asoma is an unusual type of hemivertebra distinct from lateral hemivertebra in its underlying mechanisms, its rarity, its often isolated nature and the high risk of it causing medullary compression. We report a case of isolated partial agenesis of a vertebral body (asoma) diagnosed at 23 weeks' gestation by ultrasonography, in a fetus showing hyperkyphosis with vertebral canal disruption. The diagnosis was established using ultrasound and computed tomography, which allowed measurement of the angle of kyphosis and helped in the determination of the postnatal orthopedic prognosis. In our patient, prenatal diagnosis of asoma facilitated optimization of postnatal management and reduced the neonate's risk of developing paralysis. The main anatomical parameters in the determination of the orthopedic risk are the level of the anomaly, the angle of kyphosis and the degree of vertebral canal disruption. Copyright © 2008 ISUOG. Published by John Wiley & Sons, Ltd.

CASE REPORT

A 27-year-old woman, gravida 2 para 1, was referred at 23 weeks' gestation for deformation of the fetal spine. The patient's first child had weighed 4800 g at birth and was delivered by Cesarean section. The patient had no relevant personal or family history, with the exception of untreated chronic hepatitis B. She did not suffer from diabetes (including gestational diabetes) and had not been exposed to any toxic substances. An ultrasound scan at 12 weeks' gestation had not revealed any abnormality, although the spine was difficult to observe, and second-trimester serum markers were normal.

At 23 weeks, two- and three-dimensional ultrasound scans raised suspicion of agenesis of the vertebral body

of L1 (asoma) with a normal posterior vertebral arch anatomy (Figure 1a), and showed a major deviation of the vertebral spine in the sagittal plane (fetal hyperkyphosis) (Figure 1b). The fetal motility was otherwise normal, including at the level of the lower limbs. Amniocentesis was not carried out. Ultrasound examinations at 23 and 28 weeks using a high-frequency linear probe (5–10-MHz, Siemens Medical Solutions, Erlangen, Germany) showed displacement of the posterior vertebral ligament by a triangular hypoechoic non-ossified structure. The medullary cone was displaced posteriorly without any evidence of medullary compression (Figure 1b). Computed tomography (CT) at 32 weeks with three-dimensional reconstruction confirmed isolated L1 vertebral body agenesis, but with no associated abnormalities in the adjacent vertebrae (Figure 2a). The angle of kyphosis was estimated from the scan to be 70°. The woman attended a prenatal orthopedic consultation, during which the principles of postnatal management were explained. The options for delivery were also discussed; the orthopedic surgeons proposed a prophylactic Cesarean section but our obstetric experience suggested that the risk of thoracolumbar injury during a Cesarean delivery would be similar to that for vaginal delivery.

The woman delivered a boy weighing 3260 g by vaginal delivery following spontaneous and rapid labor at term, with Apgar scores of 10 at 1, 5 and 10 min. Neonatal examination revealed no neurological problems. The dorsolumbar kyphosis was not detectable on clinical examination at rest and was observed only during flexion of the trunk. The angle of kyphosis was measured on X-ray examination as 70° in hyperflexion and 30° at rest (Figures 2b and 2c). Postnatal magnetic resonance imaging of the spine showed partial agenesis of the L1 vertebral body with a persistent cartilaginous remnant of the posterior part (Figure 3), which was retrospectively

Correspondence to: Dr C. Huissoud, Service de Gynécologie-Obstétrique, Hôpital de la Croix Rousse, 93 Grande rue de la Croix- Rousse, 69004 Lyon, Hospices civils de Lyon, Université Claude-Bernard Lyon I, France (e-mail: cyril.huissoud@chu-lyon.fr)

Accepted: 13 February 2008

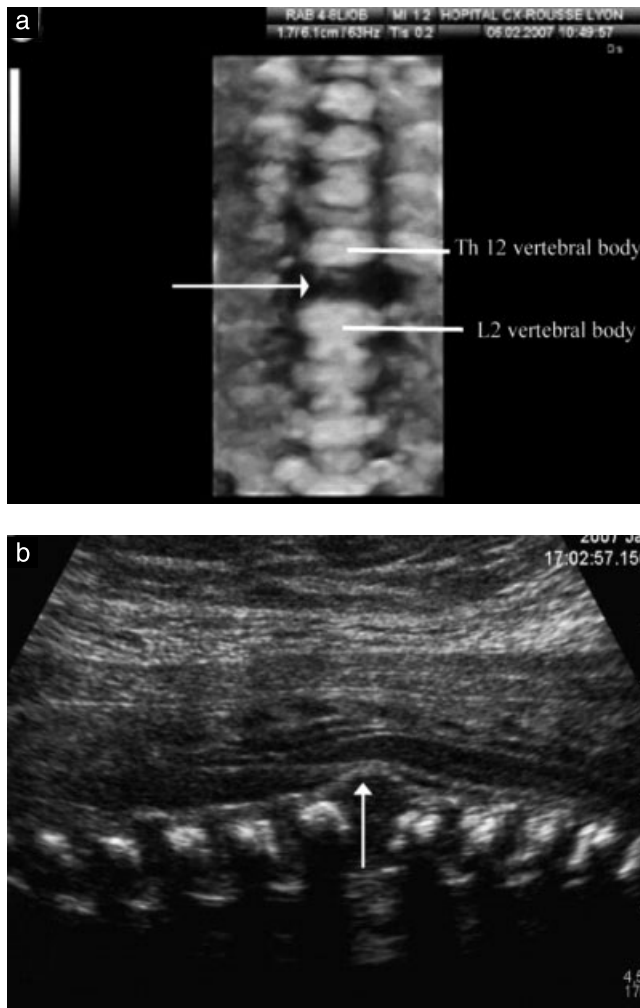


Figure 1 Ultrasound images of the fetal spine at 23 weeks' gestation. The three-dimensional coronal reconstruction shows the absence of vertebral body L1 (arrow) without induced scoliosis (a), while the two-dimensional sagittal section confirms the absence of the body at the L1 level and the recession of the posterior longitudinal ligaments with respect to the dura mater (arrow) (b).

identified as the triangular non-ossified structure seen on prenatal ultrasound examination. The vertebral spine was stabilized with a corset until arthrodesis could be carried out at 16 months of age.

DISCUSSION

During embryonic development, the spine forms rapidly from somites derived from the para-axial mesoblast. The somites differentiate into sclerotomes – the medial parts of the somites contributing to osteogenesis – and dermatomyotomes, which are involved in the skin and muscle development of the same metamere. Abnormalities that can lead to hemivertebra may occur at any stage during vertebral development. The first step in vertebra formation is the constitution of a vertebral template via migration of the sclerotome cells around the neural tube. Each pair of sclerotomes (right and left) contributes to the formation of a half-vertebra in the transverse plane and to the formation of an intervertebral disk. Two pairs of sclerotomes are thus involved in the formation of a single vertebra and its adjacent disks¹. The vertebral template develops through ossification at three points: an anterior median point, giving rise to the vertebral body, and two posterior points, each giving rise to a posterior vertebral hemi-arch. The various parts of the vertebrae (vertebral body, pedicles, processes and blades) are formed before the end of the first trimester of pregnancy, but their definitive fusion and ossification are only completed after birth^{1,2}.

Three types of mechanism lead to congenital spinal malformation: (1) defects in closure of the neural tube leading to spinal dysraphism (also known as neural tube defect); (2) abnormalities of mesoblast segmentation for vertebral fusions; and (3) formation abnormalities (hypoplasia and agenesis) resulting in hemivertebra. The defect in formation most often involves the lateral part of the vertebrae (lateral hemivertebra) leading to lateral deformation of the spine and scoliosis, but can involve, as in our case, the

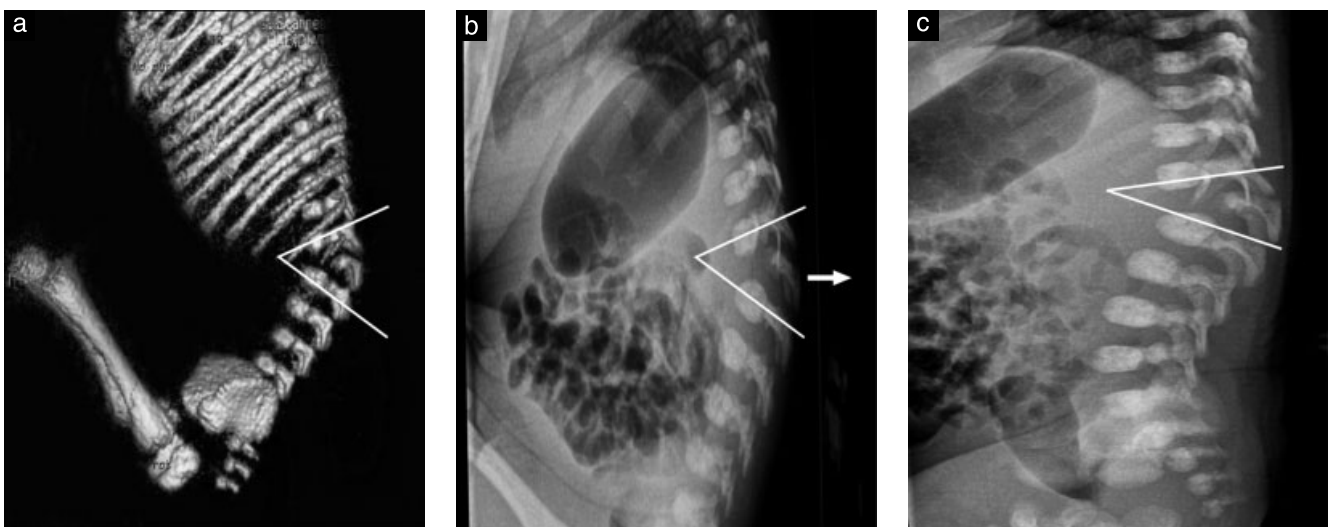


Figure 2 Three-dimensional bone reconstruction on computed tomography scan of the fetal trunk at 32 weeks' gestation, on which an angle of kyphosis of 70° was estimated (a). An identical angle was obtained by postnatal measurement on X-ray imaging in flexion conditions (70°) (b), but at rest the angle of kyphosis was only 30° (c).

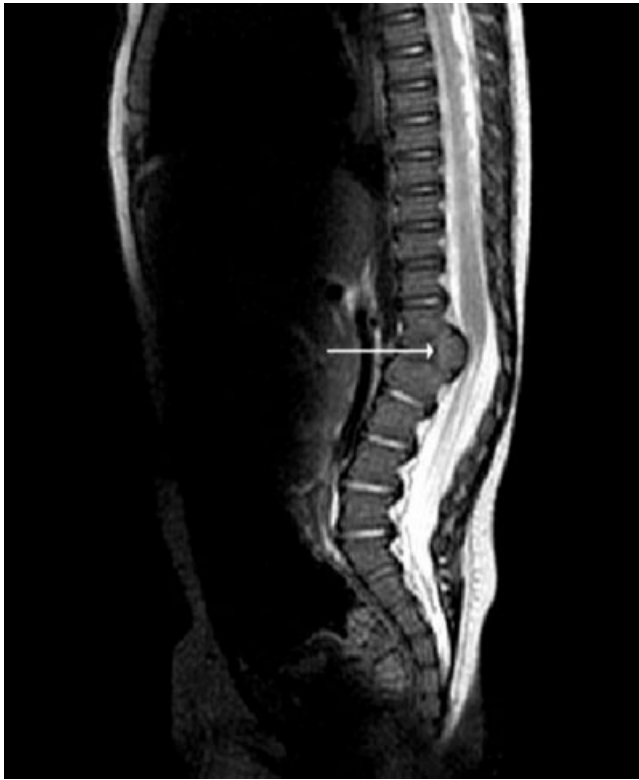

Figure 3 Postnatal magnetic resonance image (sagittal section) of the spine showing a persistent cartilaginous remnant of the posterior part of the vertebral body of L1 (arrow) corresponding to the hypoechoic triangular structure identified prenatally on ultrasound examination.

anterior or posterior part (coronal hemivertebra) leading to deformation in the sagittal plane³. In some cases, several types of abnormality may be observed simultaneously.

Lateral hemivertebrae frequently result from abnormalities in somite development, accounting for the high frequency of associated lesions (30–60%) and effects on more than one metamere. Association with malformations of the urogenital system is frequent, because the urogenital tract, like the vertebrae, is derived from the mesoblast. Nevertheless, urogenital malformation has clinical repercussions in only about 6% of cases. The prognosis of lateral hemivertebra depends, above all, on the other associated lesions, which often combine into a VACTERL-type association^{3,4}.

Coronal hemivertebra is rare and is associated with either major hyperlordosis when there are defects in the ossification of the two posterior points (involvement of a posterior arch) or kyphosis in anterior defects. The latter are not related to the failure of somite development, but are linked to a failure in the development of the anterior ossification point resulting in total or partial agenesis of the vertebral body. They often involve only one or two lumbar vertebrae, as reported by Broekman and Dorr⁵. The prognosis depends mostly on the stability of the vertebral column, and there is a risk of acute or chronic medullary compression. The neurological risk is particularly high because kyphosis is not always observed at birth, delaying diagnosis^{1,6}. However, medullary problems may be observed at birth⁷.

In our patient, prenatal imaging allowed diagnosis of L1 vertebral body agenesis and a prenatal evaluation of the orthopedic risks. In the absence of any associated abnormality, the prognosis was based principally on medullary defects and both vertebral continuity and stability, which are mainly ensured by the vertebral arches^{8,9}. Sagittal sections on ultrasound scans showed displacement of the vertebral ligament pushing the medullary cone backward but without any findings suggestive of medullary compression. Antenatal CT scan confirmed the ultrasound diagnosis and ruled out any abnormalities of the vertebral arches of L1 or adjacent vertebrae. The CT scan was also helpful in the evaluation of the severity of this malformation by measuring the angle of kyphosis, which is correlated with the risk of medullary compression, and in planning the postnatal orthopedic management. An angle of kyphosis exceeding 60° should prompt surgical intervention based on double arthrodesis (anterior and posterior) before the age of 3 years, whereas an angle less than 60° should be a potential indication for deferred posterior arthrodesis¹⁰. The prenatal imaging findings suggested a high risk of medullary compression on the basis of the 70° angle measured on CT associated with the vertebral canal disruption. However, the ultrasound and CT scans also provided some reassuring information, as there was no deformity of the posterior arches.

In our case the prenatal diagnosis had a direct impact on the early postnatal management as the deformation was not clinically evident at birth. The prenatal diagnosis also allowed informed discussion to decide the most appropriate mode of delivery. In cases of vertebral asoma, whatever the mode of delivery, the potential neurological risk should lead to precautions being taken to avoid large movements of the spine during delivery and after birth.

REFERENCES

- Kaplan KM, Spivak JM, Bendo JA. Embryology of the spine and associated congenital abnormalities. *Spine J* 2005; **5**: 564–576.
- Nolting D, Hansen BF, Keeling J, Kjaer I. Prenatal development of the normal human vertebral corpora in different segments of the spine. *Spine* 1998; **23**: 2265–2271.
- Jaskwlich D, Ali RM, Patel TC, Green DW. Congenital scoliosis. *Curr Opin Pediatr* 2000; **12**: 61–66.
- Goldstein I, Makhoul IR, Weissman A, Drugan A. Hemivertebra: prenatal diagnosis, incidence and characteristics. *Fetal Diagn Ther* 2005; **20**: 121–126.
- Broekman BA, Dorr JP. Congenital kyphosis due to absence of two lumbar vertebral bodies. *J Clin Ultrasound* 1991; **19**: 303–305.
- Lonstein JE, Winter RB, Moe JH, Bradford DS, Chou SN, Pinto WC. Neurologic deficits secondary to spinal deformity. A review of the literature and report of 43 cases. *Spine* 1980; **5**: 331–355.
- Dias MS, Li V, Landi M, Schwend R, Grabb P. The embryogenesis of congenital vertebral dislocation: early embryonic buckling? *Pediatr Neurosurg* 1998; **29**: 281–289.
- Denis F. Spinal instability as defined by the three-column spine concept in acute spinal trauma. *Clin Orthop Relat Res* 1984; **Oct**: 65–76.
- Kim CW, Perry A, Garfin SR. Spinal instability: the orthopedic approach. *Semin Musculoskelet Radiol* 2005; **9**: 77–87.
- Kim YJ, Otsuka NY, Flynn JM, Hall JE, Emans JB, Hresko MT. Surgical treatment of congenital kyphosis. *Spine* 2001; **26**: 2251–2257.